SoftwareX 12 (2020) 100510

Contents lists available at ScienceDirect

SoftwareX

journal homepage: www.elsevier.com/locate/softx

Original software publication

A MATLAB package for automatic extraction of flow index in OCT-A images by intelligent vessel manipulation

Sahar Hojati [a], Rahele Kafieh [a,*], Parisa Fardafshari [b], Masoud Aghsaei Fard [c]

[a] Medical Image and Signal Processing Research Center, School of Advanced Technologies in Medicine, Isfahan University of Medical Sciences, Isfahan, Iran
[b] Student Research Committee, School of Advanced Technologies, Isfahan University of Medical Sciences, Isfahan, Iran
[c] Farabi Eye Hospital, Tehran University of Medical sciences, Tehran, Iran

ARTICLE INFO

Article history:
Received 14 February 2020
Received in revised form 26 April 2020
Accepted 12 May 2020

Keywords:
Optical Coherence Tomography Angiography (OCT-A)
Digital image processing
Feature extraction
Blood flow information

ABSTRACT

Optical Coherence Tomography Angiography (OCT-A) is regarded as a non-invasive approach for imaging the blood vessels. New investigations on OCT-A are developed to extract structural features useful in the diagnosis and treatment of ocular diseases. Raw OCT-A is capable of providing qualitative microvascular data, but our mentioned features are intended to provide quantitative information and trustable comparison during follow ups and between different people. In this paper, we proposed an easy-to-use software to remove spurious blood vessel shadows and extract numerical features from OCT-A images. The features are expected to play an important role in the diagnosis and understanding of blood conditions. For this purpose, we used blood flow information as vessel density (VD) map (%) in a 4.5×4.5 mm rectangle scan centered on the optic disk for deep optic nerve data. Information from original image and image with small vessels were measured in whole-image (WI), peripapillary (PP) areas and theirs superior and inferior sectors. Furthermore, we also used blood flow information at parafoveal capillary as VD map in order to remove the projection artifact of superficial macular vessels from deep macular images, compatible with different analysis protocols for macula (3×3, 4×4, 5×5, 6×6, and 7×7 mm). Similarly, information from whole image and small vessels were measured in whole-image (Wi) and sector-based parafovea areas.

© 2020 The Authors. Published by Elsevier B.V. This is an open access article under the CC BY license (http://creativecommons.org/licenses/by/4.0/).

Code metadata

Current code version	*v1.0*
Permanent link to code/repository used of this code version	https://github.com/ElsevierSoftwareX/SOFTX_2020_36
Legal Code License	Apache License, 2.0
Code versioning system used	
Software code languages, tools, and services used	*MATLAB*
Compilation requirements, operating environments & dependencies	–
If available Link to developer documentation/manual	–
Support email for questions	s_hojati@hotmail.com

1. Motivation and significance

Optical Coherence Tomography Angiography (OCT-A) is a novel, depth-resolved, and non-invasive imaging method, which provides high-resolution images of retinal and choroidal blood flow and vascular structure. This method is faster and safer than conventional dye angiography, such as Fluorescein Angiography (FA), which requires the injection of an intravenous dye, and consequently leads to allergic reactions in some patients. Moreover, in comparison of OCT-A with conventional OCT, functional details of the vessels cannot be captured with a single scan in OCT [1].

However, OCT-A detects differences in amplitude, intensity or phase among consecutive B-scans, which enables movement

* Corresponding author.
E-mail address: rkafieh@gmail.com (R. Kafieh).

https://doi.org/10.1016/j.softx.2020.100510
2352-7110/© 2020 The Authors. Published by Elsevier B.V. This is an open access article under the CC BY license (http://creativecommons.org/licenses/by/4.0/).



Fig. 1. OCT Angiogram Fields of view and segmentation Layers on Angiovue. (a): Full-thickness 4.5 × 4.5 mm OCT Angiogram. (b): Macular 6 × 6 mm OCT Angiogram of "Deep" capillary plexus. (c) Macular 6 × 6 mm OCT Angiogram of "Superficial" Capillary plexus.

detection of cells within the blood vessels and blood flow [2]. Fig. 1 shows sample OCT-A from a normal eye.

In the context of feature extraction from OCT-A images, a number of previous works are available. In [3], a Hessian based multi-scale Frangi filter used on the original OCT-A image to improve the vascular flow information and to generate the OCTA vessel map for the artery–vein classification. Moreover, an adaptive image thresholding method and a bunch of morphological functions are used for cleaning the vessel map and removing small capillary mesh structures. In addition, the tracking algorithm used to extract some textural, morphological, and optical density information.

The presented method in [4], used the characteristics of the projection artifacts in 3D, specifically the tailing effect of the shadow-graphic flow, to remove the artifacts in the inner retina enface angiograms. In another method [5], using ImageJ software [6], the boundaries of the optic disk and β-zone parapapillary atrophy (PPA) are delineated. Then, parapapillary choroidal VD within the β-zone PPA region is obtained using a binary image, which was created according to the mean threshold algorithm of ImageJ.

In another method proposed in [7], the region of interest around the optic nerve head is extracted, and then, thick vessels are detected and suppressed to provide an estimation of capillary density. The proposed method in [8], major vessels is defined with a given intensity equal to 0.55 times of pixel intensities of the normalized image. Then, the major vessels, produced by the previous step, excluded from a created binary image by a local adaptive thresholding. In the next step, the capillary density is calculated after removing optic disk, located by an examiner. In [9], Gadde provides a contour map for OCT-A images using the normalized ratio of the local fractal dimension of each pixel. On this map, indices closer to 1 indicate large vessels and indices closer to 0 indicate non-vessel regions. Table 1 provides a summary of mentioned automatic methods.

The proposed software is capable of working with OCT-A from different anatomical locations (Macular OCT-A, and Deep Optic Nerve OCT-A). The main novelties of our proposed method are as follows:

1. Design of a freely available, easy-to-use software.
2. Binary segmentation of vessels with threshold determined by the user (to enable exclusion and inclusion of small vessels).
3. Optimal binary segmentation of vessels by an automatic threshold detection.
4. Detection of large spurious vessel shadows (in single deep optic nerve image) and large spurious vessel projections (from accompanying superficial image in macular data).
5. Exclusion of large vessels from OCT-A data.
6. Calculation of VD in whole image and sectoral regions before/after large spurious vessel shadow exclusion (Customized VD (CVD)).

In deep optic nerve data, the preprocessing block performs different approaches to decrease artifacts. In both macular and deep optic nerve OCT-A, the segmentation block provides information about the position of thick vessels and suppresses them to yield the desired image for measurement of the CVD. This software is already tested and used in ophthalmologic investigations and promising results in glaucoma evaluation are obtained [10]. Meanwhile, some specific results for ten randomly selected samples are provided in the Table 2.

The segmentation block on deep optic nerve data can be followed by Manual Segmentation to improve the localization of large vessels. On the other hand, the segmentation block in macular section receives two independent OCT-A data (superficial and deep images), information from which can then be used for removal of the vessels projections (which appear white).

Eventually, in the post-processing block, the software provides CVD values on the last outputs in different geometrical sectors. The motivation of this work is to design a convenient tool capable of analyzing OCT-A images and measuring the CVDs in an easy-to-use interface.

In our proposed method, the following procedures are originally developed:

- Segmentation of large vessel shadows in Deep Optic Nerve images and also large vessel projections in Macular data.
- The method for removing spurious vessels to acquire a precise vessels map
- The method for providing vessel density values in different geometrical sectors.

The needed functions for mentioned purposes are borrowed from available literature.

2. Software description

The proposed software is written in Matlab, using the GUI development environment (GUIDE), and the source code is available directly with submission. To use this software, the user can follow two different instructions based on the application:

- If you are an ophthalmologist and just want to analyze images, you need two files; First, download and install the "OCTA_Analyzer_mcr.exe". By installing this file, all of the required toolboxes and settings will be installed. Then download and run the "OCTA_Analyzer.exe" to launch the software. In this step, you would see some provided tools for analysis of OCTA images. Next, you should select the desired region, browse images and then use functions and tools to extract features based on your application.

Table 1
Comparison between different feature extraction methods.

Author	Extracted feature	Segmentation location	Available software	Feature extraction in sub-sections	Dealing with spurious vessel shadows
[3]	Artery-Vein Map	Macula	No	No	No
[4]	Vessels map	Macula	No	No	Yes
[5]	Vessel density	Deep optic nerve (β-zone-PPA)	No	No	No
[7]	Vessel density–Vessels map	Deep optic nerve	No	Yes	Yes
[8]	Vessel density	Deep optic nerve	No	Yes	Yes
[9]	Vessel density-Vessels map	Macula	No	Yes	No

Table 2
Performance metrics for the proposed method.

Sample's number	Accuracy	Specificity	Sensitivity
Average	88.43	98.91	100
1	89	98.88	100
2	95.02	99.46	100
3	89.54	98.9	100
4	90.35	98.85	100
5	83.05	98.96	100
6	84.77	99.2	100
7	89.81	98.91	100
8	88.69	98.89	100
9	89.51	98.98	100
10	84.63	98.16	100

- If you want to manipulate the code, you should download and install MATLAB (R2016b) or newer versions initially. You also need to install the "Computer vision system" and "Image Processing" toolboxes as well; Installing these toolboxes are offered to you during installing the MATLAB. Then you could adapt the source code according to your images.

The aim of this software is designing a user interface for analysis of OCT-A images. Fig. 2 shows a flowchart outlining the software architecture. 'OCT-A_ Analyzer' environment and its blocks (Pre-processing, Segmentation, Post-processing) are elaborated upon hereunder.

2.1. Pre-processing block

It is inevitable to use the pre-processing block before the main processing (segmentation) in order to improve the image quality and to lead to a more accurate segmentation. This block consists of several functions, described in the following paragraph.

In deep optic nerve data, as shown in Fig. 3, the histogram equalization is followed by a low-pass filter, with a cut-off frequency equal to 0.1 times of image size, to remove undesirable information from the image and to provide a smoothed image (Fig. 3-b). Next, a couple of morphological operations and some pixel-wise calculations, which are described below, are implemented in order to find the optic disk and its radius (Fig. 3-c):

- Creating a binary image using a given threshold equal to intensity of 123.
- A square-shaped morphological Erosion with a width of 10 pixels.
- Filling holes.
- A disk-shaped morphological Dilation with a radius of 10 pixels.
- Filling holes.
- Removing all connected objects that have fewer than 4000 pixels.
- A disk-shaped morphological Erosion with a radius of 15 pixels.
- Removing all connected objects that have fewer than 800 pixels.

2.2. Segmentation block

One of the most challenging issues in OCT-A image analysis is determining a quantitative value for VD. The correct values bring about more precise and consequently a more effective diagnosis, and treatment. One affecting issue in the calculation of VD is the presence of spurious vessel shadows in deep optic nerve data and spurious vessel projections in macular data (coming from other slobs) which accordingly changes the real value of VD. For instance, in Fig. 4 vessels shown by the marker in (b) is not real value and comes from projection effect of vessels in (c). It is necessary to localize the large retinal spurious vessels and remove them to acquire a precise vessels map for calculations of CVD. To describe this procedure, two scenarios should be considered: Segmentation of large vessels from deep optic nerve data and from the macular data. The algorithms for each case will be discussed below.

In the deep optic nerve data, the proposed method consists automatic and manual segmentation of sub-blocks. However, in the macular data, our method is comprised of deep and superficial capillary segmentation, which are elaborated in following paragraphs.

2.2.1. Deep optic nerve data

(a) Automatic segmentation

Automatic segmentation sub-block strives to find the incorrect vessels and suppress them with the aim of finding a real vessel map for calculation of CVD values.

In the first step, the location of peripapillary capillary is calculated by applying the adaptive thresholding algorithm on enface OCT-A images. This method finds the optimum threshold between two classes of the image (background and foreground) with locally adaptive thresholding using local first-order image statistics around each pixel (As shown in Fig. 5). Then, some morphological and pixel-wise operations as described in the below are performed:

- Removing all connected objects that have fewer than 30 pixels.
- A square-shaped morphological Opening with a width of 3 pixels.
- Filling holes.
- Removing all connected objects that have fewer than 400 pixels.

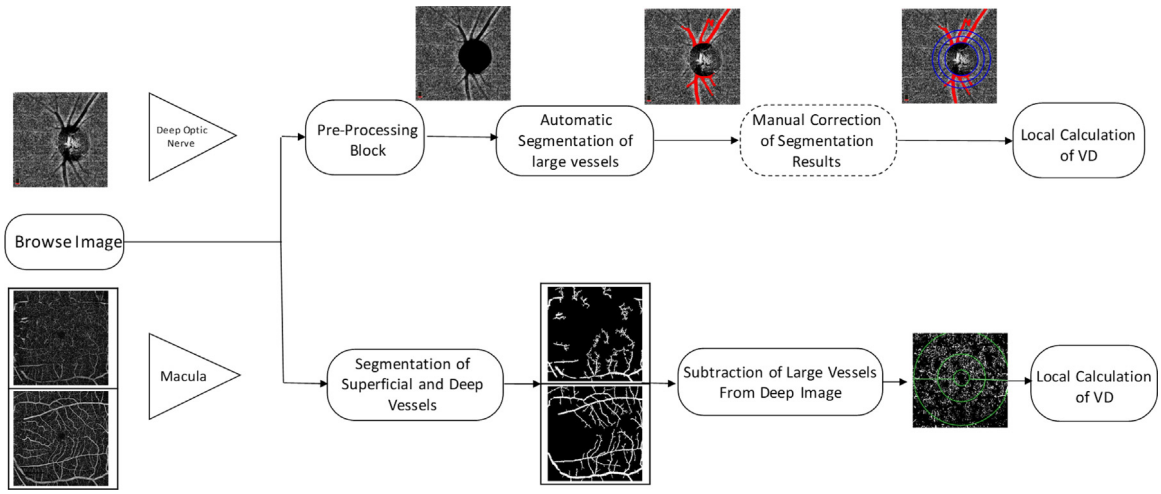

Fig. 2. Overall structure of the proposed method.



Fig. 3. Pre-processing Block in deep optic nerve data for localization of optic disk. (a): Original image, (b): Smoothed image using Histogram Equalization and low-pass filter, (c): Localization of optic disk (d): Overlaid optic disk location of deep optic nerve image.



Fig. 4. Presence of spurious vessels from other slabs in OCT-A images. (a): Deep Optic Nerve. (b): Deep Capillary Plexus, (c): Superficial Capillary Plexus.

- A disk-shaped morphological Dilation with a radius of 3 pixels.
- Removing all connected objects that have fewer than 1000 pixels.
- A disk-shaped morphological Dilation with a radius of 3 pixels.
- Removing all connected objects that have fewer than 50 pixels.

As a result, a binary image with the location of large retinal vessel shadows is created. (Union of all white locations as shadow vessels is called U).

Possible failure of the automatic algorithm in detection of vessels in complex cases, motivated design of another sub-block for manual refinement of the outputs from the previous sub-block. Namely, manual segmentation is devised to deal with possible insufficient accuracy of the automatic method.

(b) Manual Correction

The proposed hand-operated segmentation is designed to secure a desirable segmentation in sophisticated cases, by correcting the outputs of automatic method by the expert.

In our manual correction sub-block, the position of retinal vessel shadows, which could not be identified precisely by our automatic method, will be determined by user interaction. This sub-block enables the user to reach an appropriate vessel shadow segmentation based on the user needs (Fig. 2).

2.2.2. Macular data

In this part, an Otsu algorithm is applied for detection of superficial capillaries. This method uses bi-model histogram to find the optimum threshold in the image. Consequently, a binary image from superficial capillary images is constructed which includes the location of vessels in superficial image. Finally, using the result of previous step, an image similar to deep image (but with the exclusion of superficial vessel projections) is produced.



(a) (b) (c) (d)

Fig. 5. (a): Original Image, (b) Localization of optic disk, (c): Binarized image using the adaptive image thresholding method, (d): Localization of large vessel shadows.

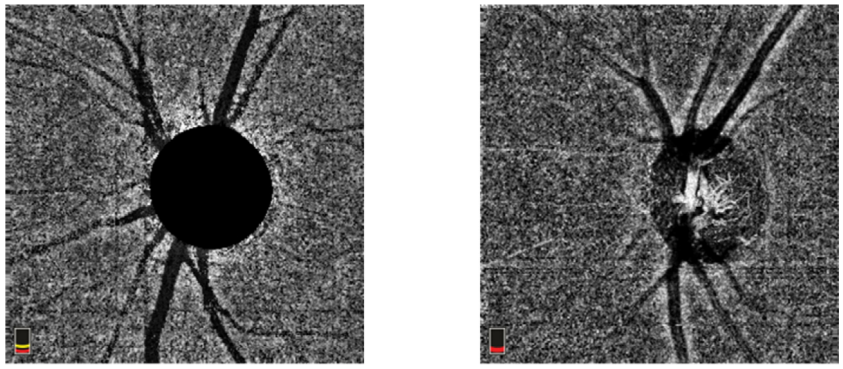

(a) (b)

Fig. 6. Different type of deep optic nerve data on different devices. (a): Dark disk, (b): Pure.

2.3. Local calculation of VD

This block is designed to provide local values for VD. Namely, instead of calculating the VD for the whole image, the values can be reported in sectors around optic disk or macula to present more precise and localized information about the vessels in such regions.

(a) Deep Optic Nerve Data

The post-processing block is designed to calculate CVD values in localized regions, which provides more important and meaningful values for ophthalmologists. The deep optic nerve images from different devices may have a dark circle on the disk location (Fig. 6-a) or may be pure (Fig. 6-b). In the second case, the algorithm, described in Fig. 3, finds the disk location automatically. Three concentric circles are then overlaid around the optic disk on enface image, (as shown in Fig. 7) in which the numerical values for CVD will calculated. The inner circle is automatically circumscribed around the disk location, and adjusts its diameter for each image. The second middle circle and the last third circle are placed homocentrically with a diameter of 1 mm and 2 mm more than the inner circle, respectively. The information on inner and outer coaxial annular regions of interest (ROI) with widths of 0.5 mm and their superior and inferior halves are then used for reporting local CVD values in populations.

In the last stage, CVD is calculated by dividing the sum of peripapillary capillary pixels on a portion of enface OCT-A image which does not contain any shadows from large retinal vessels. Eq. (1) elaborates the CVD formula to calculate the percentage of capillaries (C) on the intersection of enface OCT-A area (E) with complement on Union of shadow vessels (U).

$$CVD = \frac{Area_{white}(C)}{Area\,(E - U)} = \frac{Area_{white}(C)}{Area\,(E \cap U^c)} \tag{1}$$

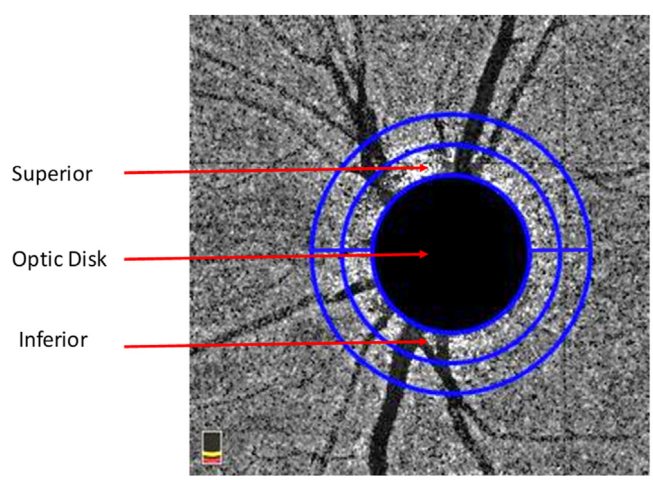

Fig. 7. Concentric circles and theirs sectors of the deep optic nerve data.

where, *Area* is the number of pixels in an image, $Area_{white}$ is the number of pixels occupied with white pixels (Capillary Density) in a binary image, E is enface OCT-A image, and ^{c} stands for complement operator. To calculate CVD in inner and outer coaxial annular ROIs and their superior and inferior halves, the *Area* operator was only calculated in desired geometrical partitions.

(b) Macular Data

Foveal Avascular Zone (FAZ) is an oval-shaped and important area next to the center of the retina. Fovea usually is in the center of FAZ; there is no vessel around it and its localization is a crucial step for calculation of CVD. In this stage, the fovea is found automatically using performing morphological "closing" operation on the binary image, produced by the previous step,

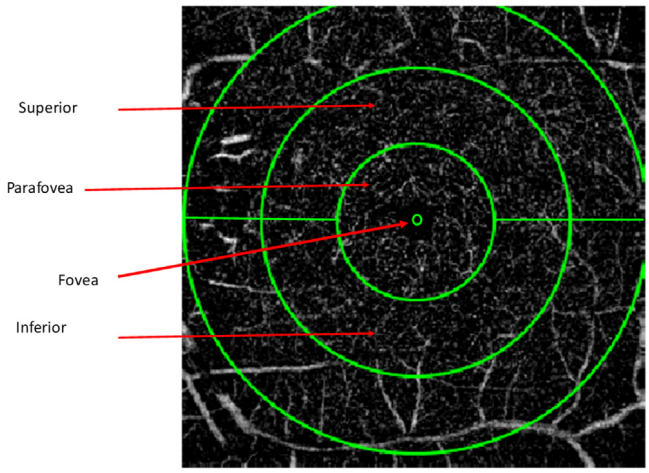

Fig. 8. A sample of OCT-A images on macula and different sectors of that.

with a disk-shaped structuring element, which has a radius of 5 pixels, and if the position is imprecise, the user can locate it manually. After finding fovea, numerical analysis is accomplished. The CVD values are obtained according to Eq. (1), here (U) is union of superficial vessel projections, and based on sector-wised regions includes superior and inferior as shown in Fig. 8, and also for the whole image. The radius of these sectors can be different and the user can select it in the software. These values are calculated for three different images include deep, superficial, and deep image without superficial vessel projections.

3. Illustrative examples

In the following section, an example of segmentation using "*OCTA-Analyzer*" is provided to illustrate the capability of this work. Fig. 5 demonstrates the overall view of our proposed software and its blocks. User can select the processing region using a pop-up menu, which includes Deep Optic Nerve, and Macula.

First of all, the original enface OCT-A image will be imported by *"Browse Image"*, then, based on the selected region, this software provides different steps for analysis. In the deep optic nerve data, according to Fig. 9, after browsing image the user can select the type of the input image based on whether it has a dark optic disk or not. Next, by pressing the 'Automatic segmentation' button, the result of its functions will be displayed. In this step, the software attempts to find the position of vessel shadows in the acquired image. If the produced output is not acceptable, the user can use manual segmentation. In Fig. 11 an enface OCT-A image and two versions of its segmentation are shown.

Next, using *"VD Calculation"*, all CVD values are calculated and exported in an '*.xlsx*' file. In this step, CVD values are measured using an adaptive threshold, however, the user can change the threshold value using a slide bar. The proposed method finds the optimum threshold using an adaptive thresholding method and the calculations can be applied based on that. Then, the binarized image obtained by the threshold will be displayed. Additionally, there is a state to have an optional threshold value by the embedded thresholding slide bar and its corresponding binarized image will be displayed, as well (As shown in Fig. 9).

In macular data, first, the user should select the size of the input image. Then, according to Fig. 10-b, after pressing the "Display Binary image" button, binary images of deep capillary plexus and superficial capillary plexus (based on the Otsu threshold method) will be displayed. Next, the user can change segmented vessels using two slide bars. The output of this step is an image, similar to the deep image but without the effect of large vessels (Coming from superficial image) (see Fig. 12). Then, after pressing the "*Ok*" button, the automatic algorithm is carried out to find the fovea in the deep capillary image. If the position is not precise, the user can change it. Next, using *"VD Calculation"* button, all CVD values are calculated and exported in a '*.xlsx*' file.

4. Impact

OCT-A is a new and non-invasive method to capture high-resolution images from blood flow in retinal and choroid vessels. Quantitative analysis of vessels, using OCT-A images, can help ophthalmologists in the diagnosis and treatment of eye disease. There are many isolated methods for vessel detection and numerical feature extraction from OCT-A data, but the aim of this work is developing and publishing a software, which includes two different modes to process for two different regions in the retina.

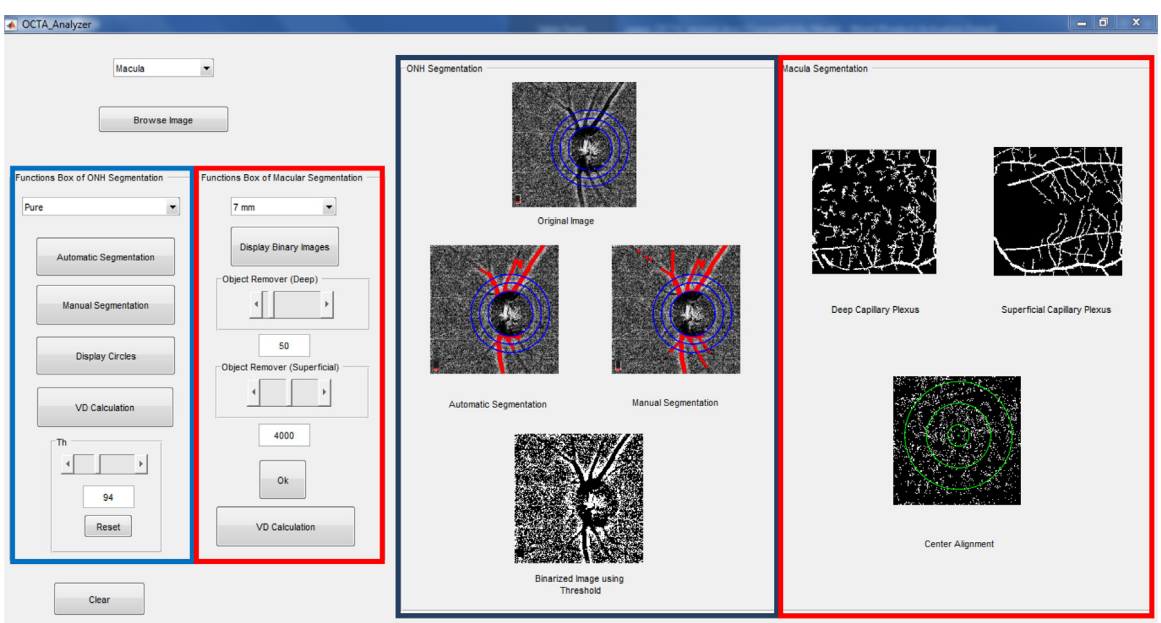

Fig. 9. Overall view of OCTA-Analyzer.



Fig. 10. Function panels for the two sections.



Fig. 11. An enface OCT-A image on deep optic nerve data, (a) Original Image, (b) Large vessel detection with Automatic segmentation, (c) Large vessel correction with Manual Segmentation.



Fig. 12. An enface OCT-A image on Macula. (a): Deep capillary plexus, (b): Superficial capillary plexus, (c): Deep capillary plexus without large vessel projections from superficial image.

Furthermore, "*OCTA-Analyzer*" embeds new efficient algorithm to measure the VD without the effects of the large retinal vessels. The main objectives to design "*OCTA-Analyzer*" software were:

- Creating a convenient tool for ophthalmologists, and researchers to provide numerical analysis on OCT-A images.
- Publishing a common software available freely for comparison of the results in different researches.
- Enabling the ophthalmologist to apply manual vessel location and even vessel selection, to provide personalized information.
- Calculating VD in a local region instead of conventional global processing.

5. Possible modifications of the code

The proposed code is compatible with the Angio Vue imaging system (Optovue, Inc., Fremont, CA, USA; RTVue XR, version 2018.0.0.18). It also may be compatible with the output images of other imaging systems, but if an image quality is totally different, a number of parameters will need alternation. As we released the source code, the user can manipulate following parameters to achieve the desired performance: (a) The number of pixels (from the vessel related objects) which will be removed. Parameters named "I" in functions named "auto_segmentation_darkdisk", and "auto_segmentation_pure", and also "II" in function named "b_vessel". (b) The size and the shape of structural elements for morphological operations. Also for the parameters "I" and "II" in the mentioned functions. (c) The threshold values for parameter "I" in the "auto_segmentation_pure" function. (d) The sensitivity of threshold function named "imbinariz".

If the user cannot configure such changes, the authors are eager to provide the possibility to customize the code. The "support email for questions" (in the code metadata description) will receive sample images and modify the code for each imaging device, due to request.

6. Conclusions

In this paper, we have proposed a software for analysis and segmentation vessels in OCT-A images. This ready-to-use program enables the user not only to have an automatic segmentation but also to have a manual version, through which the user can manipulate the automatic results to achieve a desirable segmentation and have more exact results. As future work, we will improve the procedure of our algorithm, for example, some compactness, which only occurs in a limited number of scans, is suspected of being an artifact rather than real interweaved vessel structure. We did not exclude such regions from VD calculations in current study, but this issue has potential to be considered in future works.

Declaration of competing interest

The authors declare that they have no known competing financial interests or personal relationships that could have appeared to influence the work reported in this paper.

Appendix A. Supplementary data

Supplementary material related to this article can be found online at https://doi.org/10.1016/j.softx.2020.100510.

References

[1] Lee J, Rosen R. Optical coherence tomography angiography in diabetes. Curr Diabetes Rep 2016;16(12).
[2] Carlo TE, Romano A, Waheed NK, Duker JS. A review of optical coherence tomography angiograph(OCT-A). Int J Retin Vitreous 2015.
[3] Alam M, Toslak D, Lim JI, Yao X. OCT feature analysis guided artery-vein differentiation in OCT-A. Biomed Opt Express 2019;10(4):2055–66.
[4] Liu Y, Carass A, Filippatou A, He Y. Projection artifact suppression for inner retina in OCT angiography. In: IEEE 16th International symposium on biomedical imaging. 2019.
[5] Park HY-L, Shin DY, Jeon SJ, Park CK. Associated between parapapillary choroidal vessel density measured with optical coherence tomography angiography and future visual field progression in patients with glaucoma. JAMA Ophthalmol Orig Investig 2019;137(6):681–8.
[6] Abramoff MD, Magalhaes PJ, Ram SJ. Image processing with imageJ. Biophotonics Int 2004;11(7):36–42, Available Online in https://imagej.nih.gov/ij/.
[7] Mansoori T, Sivaswamy J, Gamalapati JS, Agraharam SG, Balakrishna N. Measurement of radial peripapillary capillary density in the normal human retina using optical coherence tomography angiography. J Galucoma 2017;26(3):241–6.
[8] Geyman LS, Garg RA, Suwan Y, Trivedi V, Krawitz BD, Mo S, Pinhas A, Tantraworasin A, Chui TYP, Ritch R, Rosen RB. Peripapillary perfused capillary density in primary open-angle glaucoma across disease stage: An optical coherence tomography angiography study. Br J Ophthalmol 2017;101(9):1261–8.
[9] Gadde AGK, Anegondi N, Bhanushali D, Chidambara L, Yadav NK, Khurana A, et al. Quantification of vessel density in retinal optical coherence tomography angiography image using local fractal dimension. Invest Ophthalmol Vis Sci 2016;57(1):246–52.
[10] Aghsaei Fard M, Salabati M, Mahmoudzadeh R, Kafieh R, S. Hojati, Moghimi S, et al. Automated evaluation of parapapillary choroidal microvasculature in ischemic optic neuropathy and open angle glaucoma. Invest Ophthalmol Vis Sci 2020;61(3).